

Neurology 2019

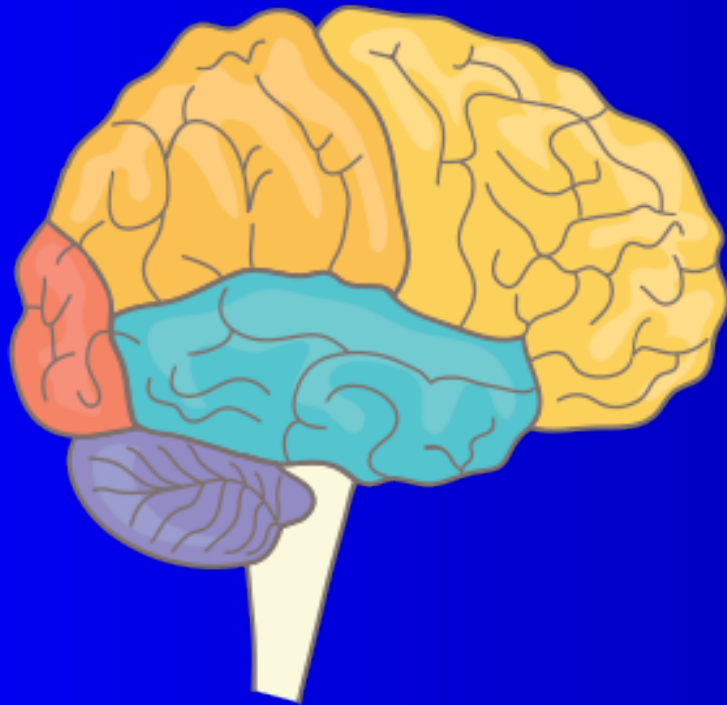
Test your Knowledge

Mikko Kallela, Olli Häppölä

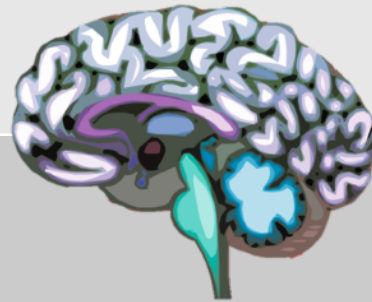Department of Neurology

Helsinki University Central Hospital

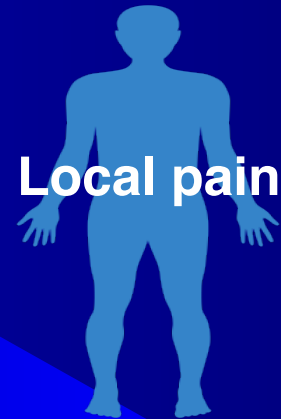How you make the difference between central and peripheral disorders



Clinical findings	Upper motor neuron	Lower motor neuron
Muscle weakness	Yes	Yes
Atrophy	No	Yes
Fasciculations	No	Yes
Reflexes	Increased Babinski sign	Decreased No Babinski sign
Muscle tone	Increased (spasticity)	Flaccid



**Musculo
skeletal
system**



Psyche

**Neuroexam
normal**

The NeuroLevel and NeuroExam

Neurological Examination

Cognition

Cranial Nerves

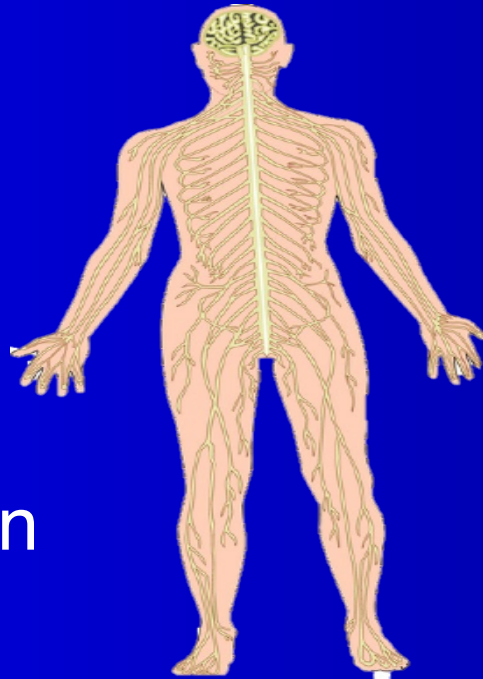
Motor examination

Cordination

Sensory Examination

Reflexes

The Autonomic Nervous
System



Neurological Level

Psyche

Cerebral hemispheres

Basal ganglia

Brainstem and cranial
nerves

Cerebellum

Spinal cord

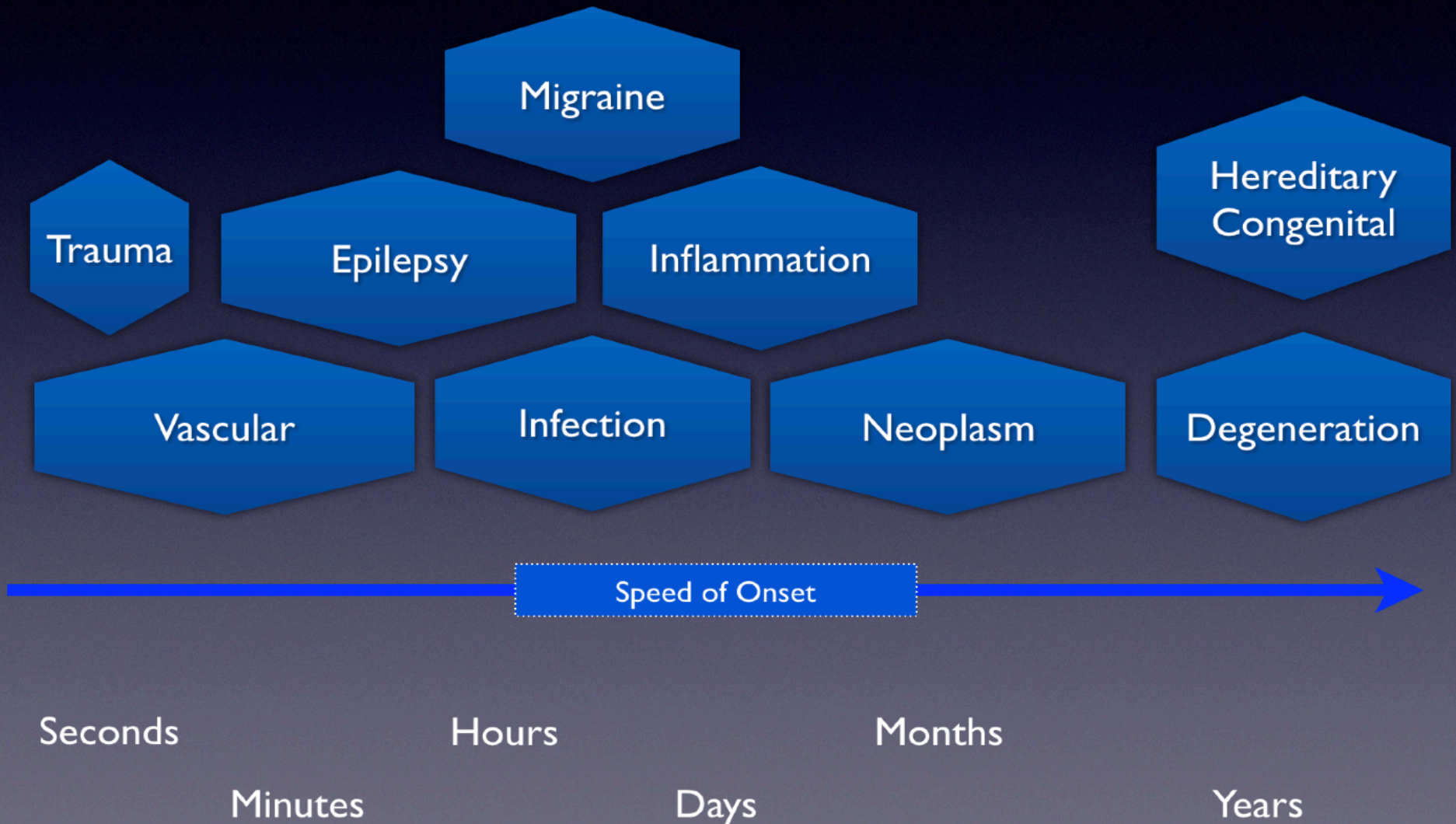
Nerveroot

Peripheral nerve

Myoneural junction

Muscle

The Timescale of Neurological Symptoms



Frontal

What does it do?

Temporal

What does it do?

Lobes of the Brain


Parietal

What does it do?

Occipital

What does it do?

Where is the problem?





Which cranial nerve?




Which cranial nerve?



Peripheral or Central Paresis of Cranial Nerve VII?



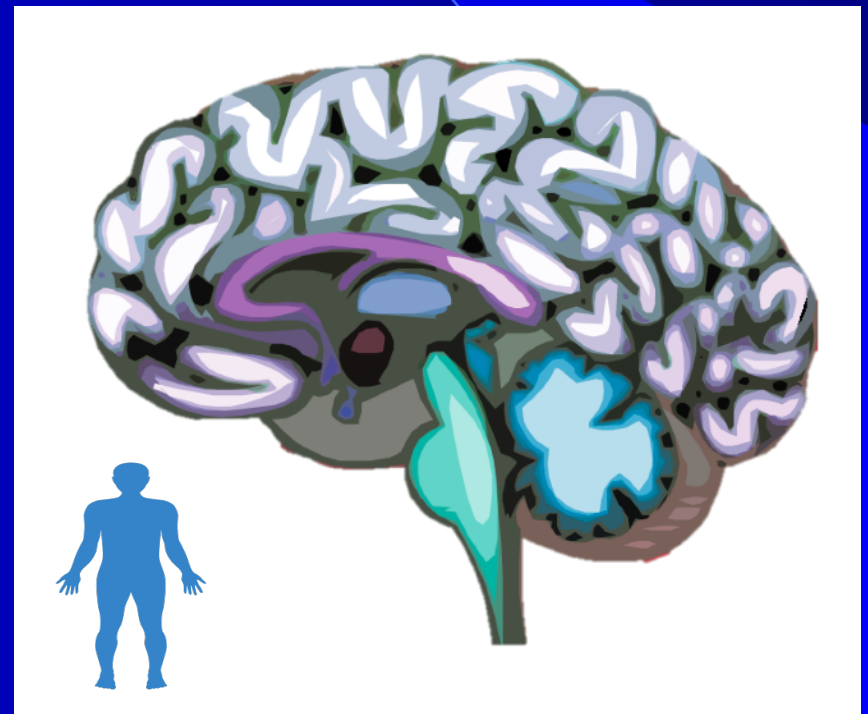
What is the finding? Where is the problem ?



Where is the lesion?

Neurological Level
Cortex
Subcortical white matter
Subcortical gray matter
Cerebellum
Brainstem and cranial nerves
Spinal cord
Nerve root
Brachial plexus , lumbosacral plexus
Peripheral nerve
Neuromuscular junction
Muscle

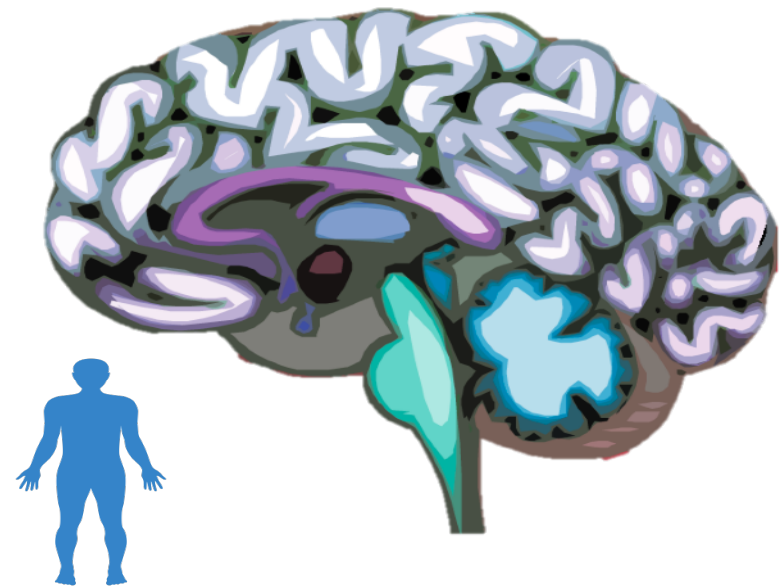
**Amnesia, aphasia, apraxia,
visuospatial deficits, neglect,
epileptic seizures**



Where is the lesion?

Neurological Level
Cortex
Subcortical white matter
Subcortical gray matter
Cerebellum
Brainstem and cranial nerves
Spinal cord
Nerve root
Brachial plexus , lumbosacral plexus
Peripheral nerve
Neuromuscular junction
Muscle

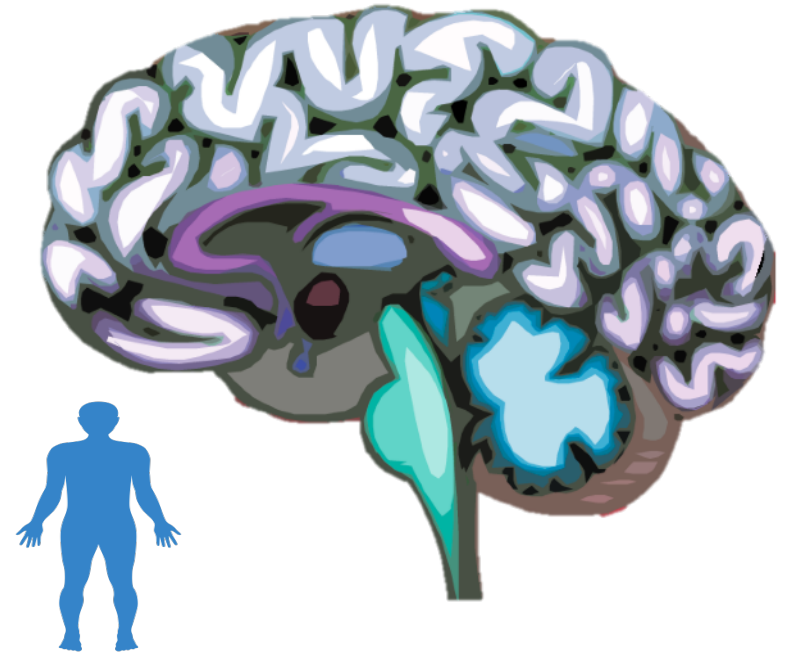
Visual field deficits, dense numbness, complete hemiparesis, executive dysfunction, and decreased psychomotor speed



Where is the lesion?

Neurological Level
Cortex
Subcortical white matter
Subcortical gray matter
Cerebellum
Brainstem and cranial nerves
Spinal cord
Nerve root
Brachial plexus , lumbosacral plexus
Peripheral nerve
Neuromuscular junction
Muscle

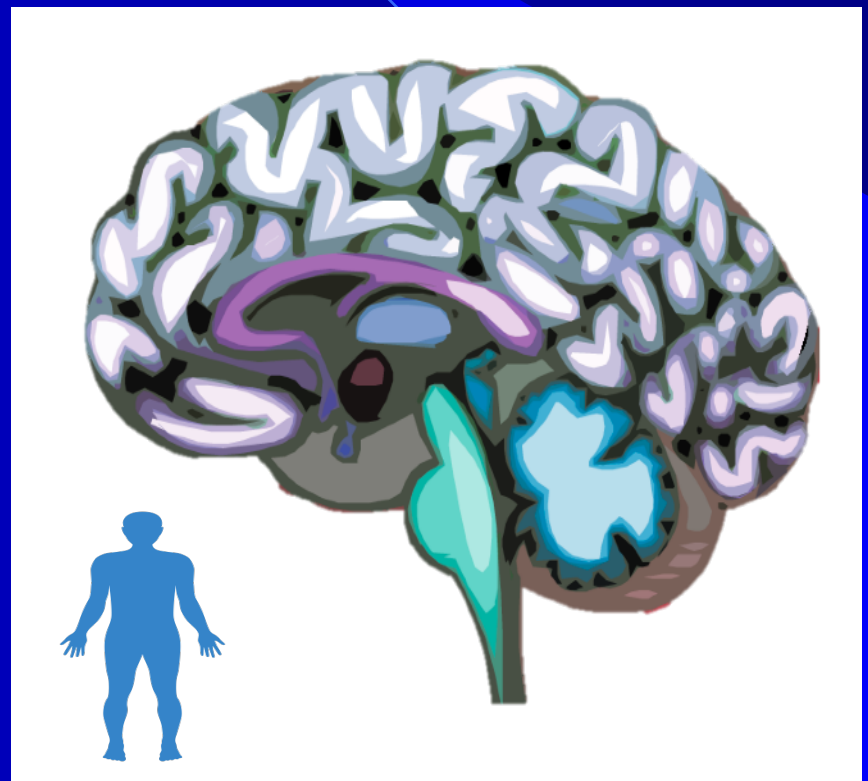
**Tremor, bradykinesia, rigidity,
postural instability
(parkinsonism)
= mnemonic TRAP**



Where is the lesion?

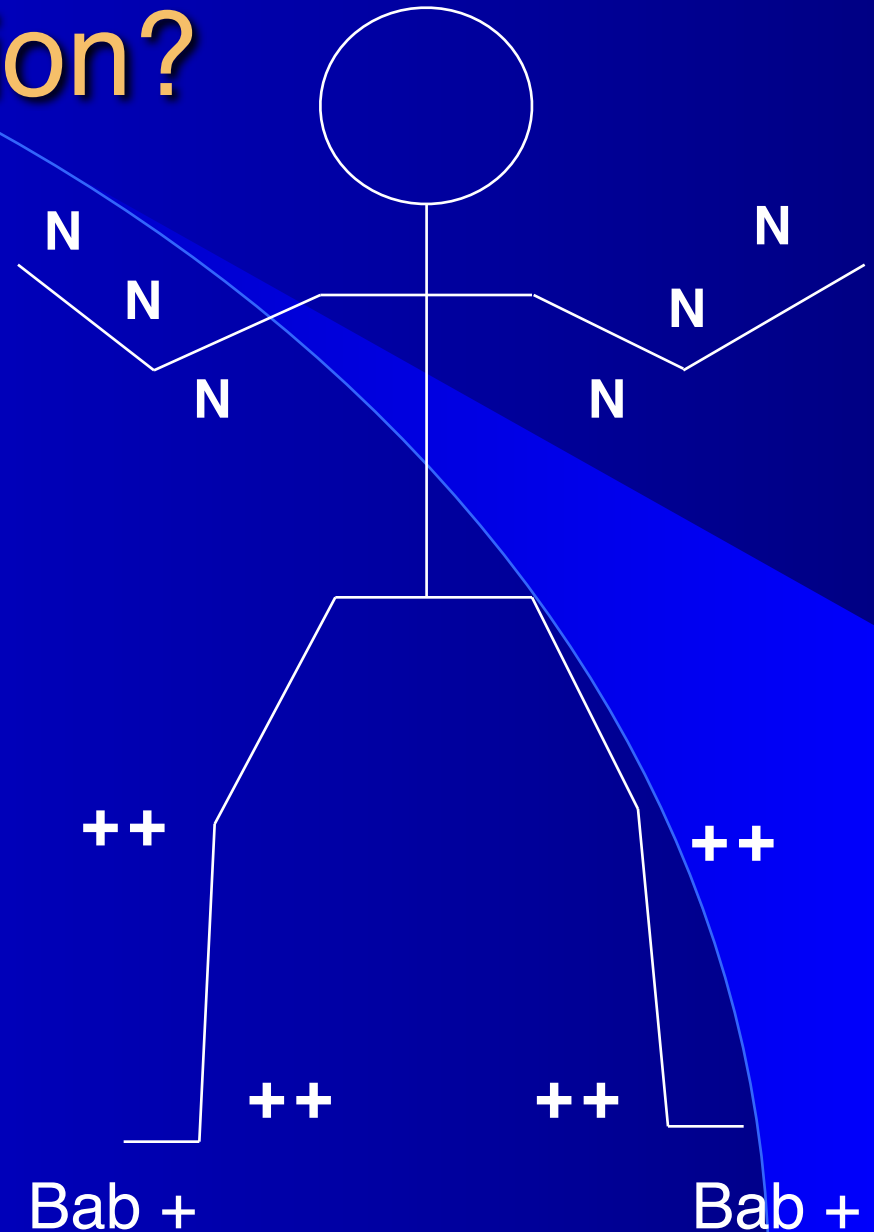
Neurological Level
Cortex
Subcortical white matter
Subcortical gray matter
Cerebellum
Brainstem and cranial nerves
Spinal cord
Nerve root
Brachial plexus , lumbosacral plexus
Peripheral nerve
Neuromuscular junction
Muscle

**Proximal, symmetric weakness;
no sensory symptoms**




Where is the lesion?

Psyche
Right hemisphere
Left hemisphere
Basal ganglia
Cerebellum
Cervical spinal cord
Thoracic spinal cord
Lumbar spine
Nerve root
Peripheral nerve
Myoneural junction
Muscle



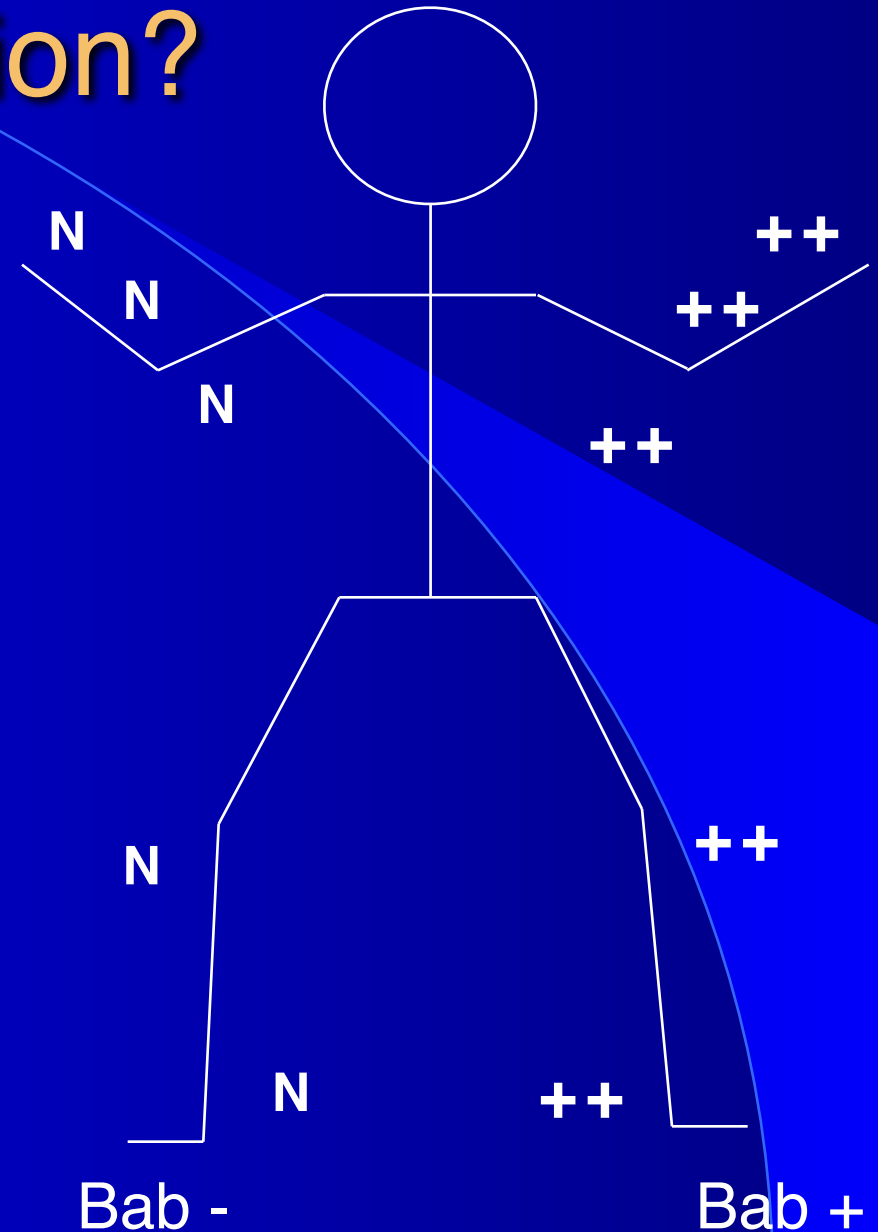
Where is the lesion?

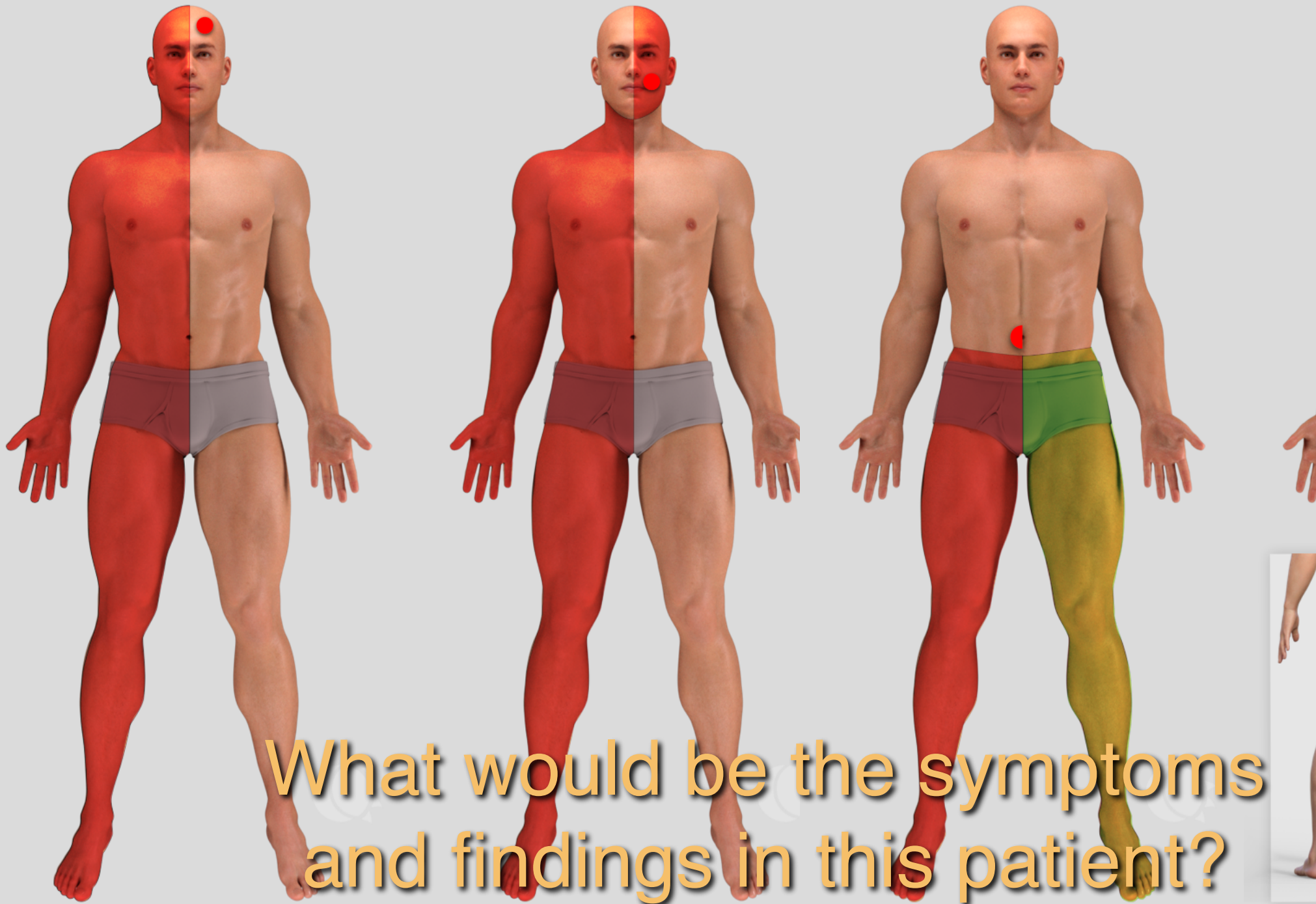
Psyche
Right hemisphere
Left hemisphere
Basal ganglia
Cerebellum
Cervical spinal cord
Thoracic spinal cord
Lumbar spine
Nerve root
Peripheral nerve
Myoneural junction
Muscle




Where is the lesion?

Psyche
Right hemisphere
Left hemisphere
Basal ganglia
Cerebellum
Cervical spinal cord
Thoracic spinal cord
Lumbar spine
Nerve root
Peripheral nerve
Myoneural junction
Muscle





What would be the symptoms and findings in this patient?



What is presented here – what is the problem?